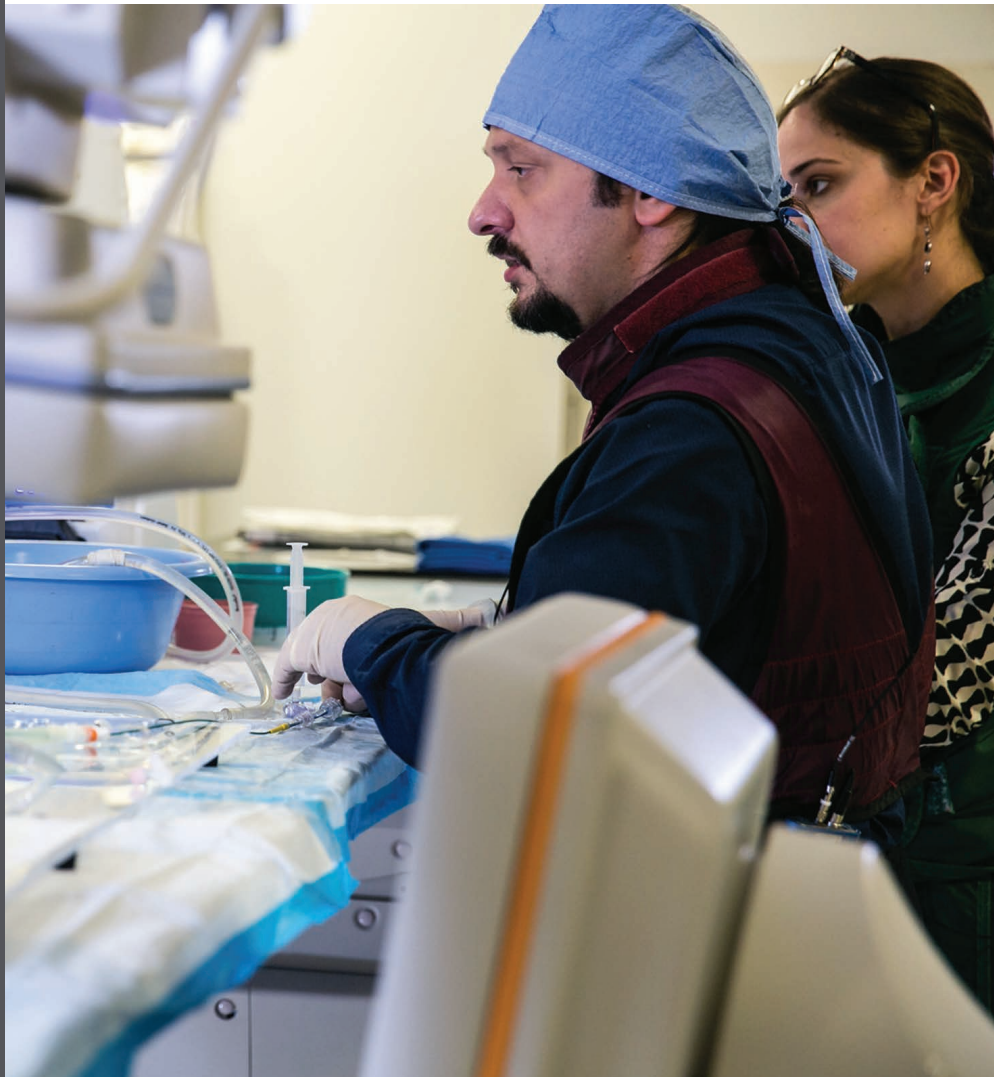
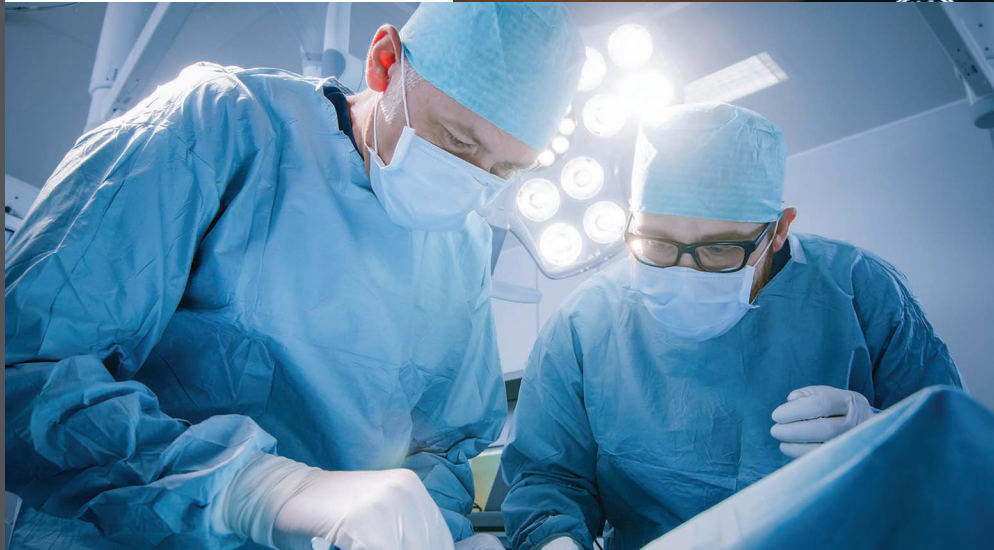
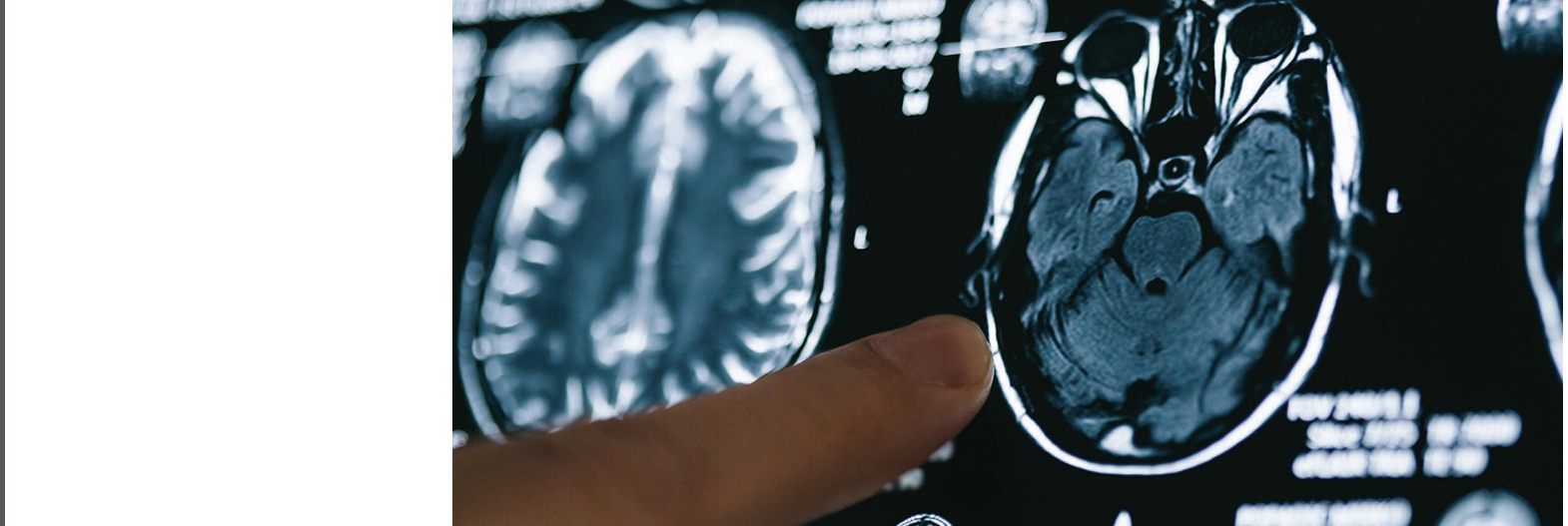

Current and Future Perspectives in Neurosurgical Applications

Jacobs Institute



Introduction

The field of neurosurgery has experienced significant advancements as a result of 3D printing. This is not surprising given that most of the surgical procedures and corresponding pathologies that neurosurgeons encounter are exquisitely complex, involving intricate, minute anatomical structures, that cannot always be sufficiently appreciated via two-dimensional multi-planar imaging (1). Although it is true that diagnostic imaging has evolved from 2D renderings, these images are still viewed on a flat 2D computer screen. This makes interpretations related to depth difficult, forcing a surgeon to mentally construct complicated vasculature.

Accurate 3D models of patient-specific anatomy enable visualization of anatomical structures from different angles and also facilitate procedural skills practice. The latter is particularly important in the field of neurosurgery, due to the high-stakes nature of procedures within this specialty, and the otherwise slow, step-wise accumulation of operative skill when working with real patients (1,2). In addition to surgical planning and procedure simulation, 3D models have contributed to the development of customizable, patient-specific neurosurgical implants and prosthetic devices.

Recent publications have described a vast array of applications for 3D printing in several subspecialties of neurosurgery. These areas include cerebrovascular, neuro-oncologic, spinal, functional and endoscopic neurosurgery. Clinical applications include the treatment of

pathologic cerebral vasculature, brain tumors, spinal cord conditions, treatment-resistant neurological disorders, and remotely located pathology, respectively. Each of these fields has uniquely harnessed 3D printing to advance surgical planning, training and treatment for improved patient outcomes.

The first section of the present review will provide an overview of the literature that has been published since Randazzo and associates' 2016 systematic review on the use of 3D printed patient-specific models for presurgical planning and physician education (3). The second section will then look at how some of the themes identified in the literature are at work in presurgical planning and training simulation at the Jacobs Institute/Gates Vascular Institute (JI/GVI) in Buffalo, New York. The review will conclude with some hypotheses for the future role of 3D printing in neurosurgery that can be made based on the recent literature and 3D printing practices at the JI/GVI.

Residents work on the 3D printed models with Dr. Siddiqui.



Section One:

Review of the Use of 3D Printed Models for Presurgical Planning in Neurosurgery

In their 2016 systematic review of 3D printing in neurosurgery, Randazzo et al. reviewed 36 published studies in the three main areas in which neurosurgery incorporates 3D printing. These areas include:

- The creation of patient-specific anatomical models for surgical planning, training and education
- The design of neurosurgical devices for assessment and treatment of neurosurgical diseases
- The development of biological tissue-engineered implants

They found that 12 studies were related to cerebrovascular surgical planning and training applications, six were related to neuro-oncology applications, four were related to functional applications, five were related to spine surgery, six were related to endoscopic applications, two were review articles and two were related to other subspecialties of neurosurgery.

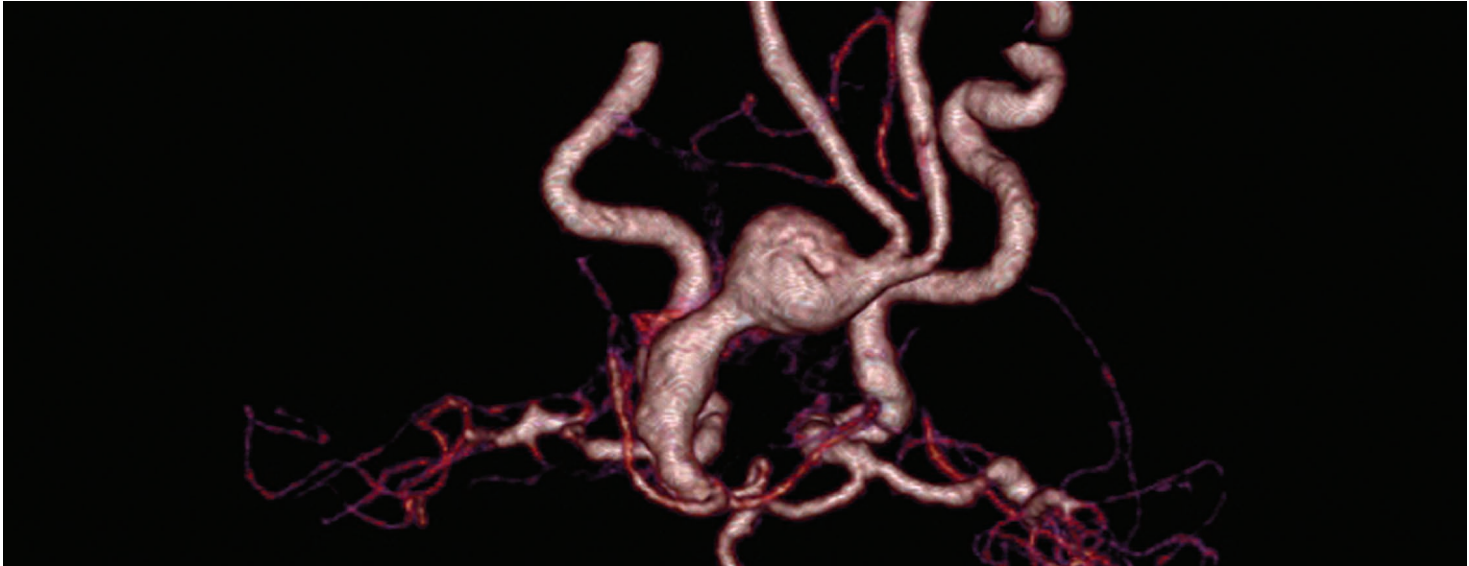
Within the group of studies related to cerebrovascular applications, three of the studies reviewed why 3D models are needed (4,5,6). The authors argued that viewing aneurysms on a flat 2D computer screen during image review or fluoroscopy — even with computationally reconstructed 3D visualization — makes interpretations related to depth difficult. They concluded that physical models represent a potentially more advantageous method of visualization. In terms of training, several of the studies pointed out that surgical simulation using 3D printed models is valuable in light of the need for a safe teaching environment and the new training restrictions that have limited patient interactions for medical students (7,8,9,10). Nine of the studies confirmed that the complex vasculature obtained

from patient scans can be accurately printed using 3D printing (4,5,6,8,11,12,13,14,15). They verified the anatomical accuracy of 3D printed models using different validation methods, including statistical analysis of aneurysm diameter measurements relative to DSA images, computational comparison of re-imaged models and DSA images, visual comparison of model and CTA and clinician quality assessment. Two of the studies reported on the use of anatomically accurate models to improve surgical planning for aneurysm and pediatric arteriovenous malformation (AVM) treatment (4,8).

Treatment of complex neurovascular lesions such as AVMs requires careful application of meticulous surgical and/or endovascular technique. In particular, risk is especially elevated in children who have smaller blood volumes, complicated anesthetic requirements, and more difficult surgical and endovascular access compared with adults. Weinstein and his colleagues at Boston Children's Hospital point out that despite the availability of 3D multi-planar imaging, understanding relational 3D anatomy for complex cerebrovascular lesions such as AVMs, can be difficult and requires scrolling through multiple images (8). Even simulated 3D reconstructions on-screen lack easy manipulation and do not provide tactile feedback. Their AVM study applied PolyJet™ technology, which combines multiple colors and materials simultaneously to replicate and differentiate cerebral vascular structures for instantaneous visualization of the anatomy of the lesion from all perspectives. It also allowed the user to practice operative approaches through multiple corridors or pathways of attack using actual surgical instruments for realistic haptic feedback.

Section One

(cont.)



They demonstrated a 12 percent or 30 minute reduction in operative room time in two cases following the use of 3D printed patient-specific models for preoperative surgical simulation when compared with matched controls. The authors noted that the models aided in understanding relational anatomy for safe identification of the vessels. Specifically, the use of multicolor and high-resolution PolyJet technology provided enhanced visualization of each complex lesion, differentiating its nidus, normal vessels such as the feeding arteries or draining veins, and spatial relationship to the surrounding vessels and structures. A thorough understanding of these aspects is critical to determining the optimal intervention and its success.

The present systematic review builds on the findings from the studies related to cerebrovascular applications and reviews them in light of the literature that has been published since 2015. A PubMed search was done using keywords to identify relevant literature between December 2015 (when the Randazzo et al systematic review was conducted) and July 2018. As in the Randazzo study, inclusion criteria included

articles referencing both “3D printing” or “additive manufacturing” and “neurosurgery”. The 170 results were manually searched and ten were new articles related to cerebrovascular applications. Two additional articles resulted from additional searches referencing “additive manufacturing” and “neurosurgery” and “3D printing” and “surgical planning endovascular”. Of the 13 relevant articles (Table 1), two were published in 2015, but not included in the Randazzo study.

Like the studies included in the Randazzo systematic study, the twelve articles published since 2015 make the case for the use of 3D printed models in medical training and presurgical planning, verify the accuracy of the models, and report on the use of models to improve preoperative planning. Two of the studies report on technological developments that can advance the 3D printing process. Taken together, the recent studies suggest that 3D printed models represent a paradigm shift in both medical education and presurgical planning — a shift that will ultimately enhance patient care and outcomes.

Section One

(cont.)

Several of the studies (16,17,18,19,20,21,22,23) identified the opportunities presented by 3D printed models for use in preoperative planning, which allows surgeons to adjust treatment plans before the patient is actually in the room and to prepare for initially unanticipated challenges. Three of the studies (22,23,24) reviewed the drawbacks of traditional presurgical planning, observing that there is a great difference between information obtained from medical imaging and the actual tissues or organs in the human body and that it is difficult to predict the behavior of devices using 3D images on a screen. They point out that an ordinary planar 3D image is merely a 2D image created with perspective techniques, so it gives no stereoscopic sense in the still state. They explain that the perception of the image on the monitor as being 3D is produced by image processing in the viewer's brain based on parallax caused by facts such as image movement, memory, knowledge, and experience. They found that 3D printed models can perfectly capture aneurysmal and parent vessel geometries, as well as vascular branches.

3D printed models offer the physician adequate visualization of surrounding structures and clear identification of all involved vessels, giving them a clear understanding of 3D spatial relationships. Thawani et al. argue that the models can be used together with 3D angiographic reconstructions to better describe the 3D vascular anatomy and flow associated with patients' AVMs (20). Several argue that because of these advantages, presurgical planning with 3D printed models can better inform treatment decisions and will ultimately reduce fluoroscopy time, contrast volume, and overall procedure time during the actual case (18,19,21,22,23).

Two of the studies aimed to quantitatively measure the actual impact of using 3D printed models for preoperative planning. Wang et al. printed simulation models of 13 aneurysm patients that included parent vessel geometries, as well as vascular branches

(22). They used the models to help decide between aneurysm clipping and endovascular coiling. The modified Rankin scores of all of the patients were favorable two months after treatment. Dong et al. evaluated the use of medical models for surgical planning and patient consultation (23). Fourteen patients undergoing elective endovascular treatment for brain arteriovenous malformations (bAVMs) were selected and divided evenly into a control group without the use of 3D printed models and a trial group with the use of 3D printed models. The authors found that the preoperative patient/family education satisfaction and acceptance of the planned procedure was significantly higher and the time required to obtain informed consent was shortened by 33 percent when the 3D printed models were used.



Despite the use of multi-planar imaging with three modalities (MRI, CT angiography, and catheter arteriography), understanding relational 3D anatomy can be difficult. Visualization of detailed anatomical structures can require scrolling through multiple images, and even simulated 3D reconstructions on-screen lack easy manipulation and do not provide tactile feedback. A 3D printed model allows for instantaneous visualization of lesional anatomy from all perspectives, with the added ability to simulate surgical approaches with tactile feedback and use of actual surgical instruments to practice approaches through multiple corridors of attack.”

Adnan Siddiqui, MD, PhD,
Chief Medical Officer, Jacobs Institute
Director Neurosurgical Stroke Service, Kaleida Health
Director of Neuroendovascular Fellowship Program,
State University of New York at Buffalo

Section One

(cont.)

Additionally, the time to get from intraoperative DSA data to the start of endovascular treatment was reduced by nearly half (47 percent) when physicians used the models to formulate a treatment plan compared to the controlled group (Table 2). They also noted that surgeon participants got thorough stereoscopic and rotational views of the bAVM structure including feeding arteries, nidus, and draining veins preoperatively using 3D printed models, so the corresponding treatment strategies, such as which artery to embolize and what embolization material to use, had already been made before DSA images were obtained. They also emphasized that an actual solid model of the preoperative 3D surgical anatomy may potentially reduce operative time and surgical risks, which is of great benefit to the patients.

In addition, Dong and his associates point out that 3D printed models can also provide real-time intraoperative monitoring in the following aspects: (1) the extent of embolization in endovascular treatment or tumor excision in microsurgery, (2) the location of residue nidus and its relationship with feeding arteries and draining veins, and (3) the positional relationship of the lesion and surrounding structures. All of which improves therapeutic efficacy and decreases surgical complications.

The anatomical accuracy of the 3D printed models was assessed in several of the studies (20,21,23).

They found high levels of fidelity with images using 3D rotational angiographic data and other verification modalities. In the Dong et al. study, measurements on seven of the models and intraoperative DSA imaging were taken in triplicate and compared for deviation (23). High fidelity was found between the models and DSA images. In the Thawani et al. study, the authors used caliper measurements of the model and found that the model represented imaging findings to within <0.1 mm (20). Frölich et al. compared aneurysm volumes in the models and in the patient data and found that a high level of anatomical accuracy was achieved (21).

Current limitations with 3D printed models were explored in three of the studies, along with the ways that the models and the processes used to produce them can be improved (21,24,26). Commenting on the use of Fused Deposition Modeling (FDM®) for the production of aneurysm models replicating patient-specific anatomy, Frölich et al. observed that while a high level of accuracy was achieved when comparing images of the models with the original patient clinical scans, vessel segments <1 mm were not reliably reproduced or obstructed, which may represent a limitation of the FDM technique for manufacturing very small vascular branches and aneurysms (21). Material jetting may offer better spatial resolutions. Another limitation is the rigidity of the FDM models. This means that they do not realistically respond to catheter or coil forces, limiting

Table 2. The influence of 3D models on informed consent, treatment planning and degree of patient satisfaction¹.

	N	Informed Consent, Minutes	Treatment Planning, Minutes	Degree of Satisfaction
With Model	7	10.30 ± 0.80	5.50 ± 0.40	9.40 ± 0.60
Without Model	7	15.40 ± 1.30	10.40 ± 1.60	8.20 ± 0.30
T Value		8.84	7.86	4.73

3D = three-dimensional, N = number; min: minute.

¹ Dong M, Chen G, Li J, Qin K, Ding X, Peng C, Zhou D, Lin X. Three-dimensional brain arteriovenous malformation models for clinical use and resident training. *Medicine*. 2018; 97(3):e9516.

Section One

(cont.)

the degree of realism when simulating procedures such as coil embolization. The authors observed that, “Several critical parts of neurointerventional procedures depend heavily on the elasticity of the anatomic structures, such as the dislocation of catheters or coils, ruptures of aneurysms, and movement of vessels in the access path. Accurate reproductions of these properties will greatly increase the degree of realism.” Again, material jetting may offer solutions.

Two of the studies looked at improvements in model production that could reduce printing time. Aoun et al. speculate that breakthroughs using Continuous Liquid Interface Production (CLIP™) will speed up 3D printing of patient-specific simulation models 100-fold (26). Kaneko et al. found that low-cost desktop printed vascular models can be smoothed with minimum change in conformity using an acrylonitrile butadiene styrene (ABS) solvent, which is considerably faster and less labor intensive than the standard smoothing method that is currently used (24).

The shortcomings of traditional methods of neurosurgical training were reviewed in four of the studies (16,17,18,27). The authors argued that traditional training methods using animals, cadavers, and plastic models lack realism and are neither convenient nor practical for daily practice. They noted that these shortcomings are amplified by changes in training restrictions on work hours and supervisions requirements. They maintained that 3D printed models address these challenges and allow surgeons to practice cases as many times as desired, which facilitates procedural skill acquisition.

Dong reported on 30 surgical residents from one residency program who evaluated 3D patient-specific bAVM models and provided feedback on their resemblance to real bAVM structures and the usefulness of a printed model

The result of the residents' assessment, which was based on 5-point Likert scales where 5 represents the highest rank and 1 represents the lowest rank.¹

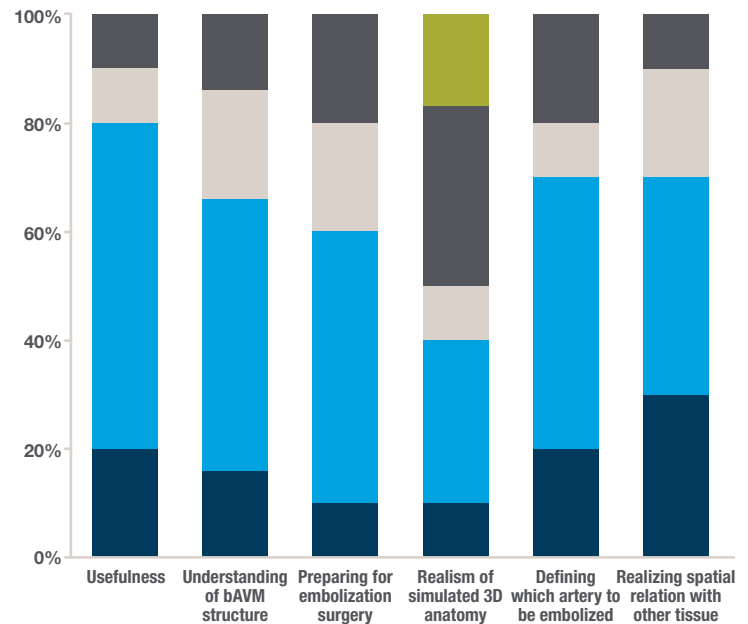


Figure 1.

¹ Dong M, Chen G, Li J, Qin K, Ding X, Peng C, Zhou D, Lin X. Three-dimensional brain arteriovenous malformation models for clinical use and resident training. *Medicine*. 2018; 97(3): e9516.

Strongly disagree Disagree Neutral Agree Strongly agree

as an educational tool (23). The bAVM models as a teaching method obtained the highest score in all the survey questions concerning their overall usefulness (Figure 1). The participants gave high scores on the ability of bAVM models to build on residents' current understanding of bAVM anatomy. The question whether the bAVM models helped them to prepare for the delivery of bAVM endovascular treatment (choosing which artery to embolize) was also rated highly by residents. When asked to what extent the models mimic real anatomy, the scores were moderate (40 percent) because the residents thought the models did not provide detailed information about structures within the nidus. This is clearly an area that may be addressed with material jetting and new, digital materials.

Clipping of cerebral aneurysms is still an important skill in neurosurgery. As endovascular treatment for cerebral aneurysms increases, neurosurgical residents have less experience performing surgery. As such, training for clipping has become difficult. One solution is simulation surgery.

Tenjin and Okano developed 3D patient-specific models of fourteen aneurysms for training on cerebral aneurysm clipping (27). The models were used to train neurosurgery fellows and residents on three-dimensional manipulation using an operating microscope, the clipping procedure, and how to react to unexpected events during surgery, such as premature rupture. To achieve the latter, the aneurysm model was perfused with simulated blood. One training course was held with eight residents.

For aneurysm clipping, the order of dissection of arachnoid, veins, arteries, and aneurysm along with the direction of instrument insertion, and pressure of the spatula are important points. The authors concluded that the residents were successfully trained on each of these critical areas using the 3D patient-specific models of the aneurysms and surrounding structures. In addition, the residents reported that the course was useful in helping them to determine how to: position, perform the craniotomy, manipulate the instruments, dissect the aneurysm, and clip. The authors noted that a key advantage the models offered was that they allowed three-dimensional manipulation of the aneurysms and surrounding structures.

Table 1. Description of 3D Printing Method by Study

Study Authors	Study	Application	Fabrication Method	Structure(s) Printed	Printer	Material(s)
Aoun et al. (2015)	Futuristic Three-Dimensional Printing & Personalized Neurosurgery	T/S (Potential)	Continuous Liquid Interface Production	Patient-Specific Simulation Models	Continuous Liquid Interface Apparatus	Resin
Russ et al. (2015)	Treatment Planning for Image Guided Neuro-Vascular Interventions Using Patient-Specific 3D Printed Phantoms	P/M	PolyJet	Two Patient-Specific Circle of Willis and a Coronary Model	Objet Eden260V™	TangoPlus™ (Semitransparent Elastic Material)
Frölich et al. (2016)	3D Printing of Intracranial Aneurysms Using Fused Deposition Modeling Offers Highly Accurate Replications	P/M; T/S (Potential)	Fused Deposition Modeling	Ten Patient-Specific Aneurysm Models	Design-jet Color 3D Printer (Hewlett-Packard Development Company)	ABS
Singhal et al. (2016)	Improved Surgery Planning Using 3-D Printing: a Case Study	P/M	NA	NA	NA	NA
Kaneko et al. (2016)	Manufacture of Patient-Specific Vascular Replicas for Endovascular Simulation Using Fast, Low-cost Method	P/M; T/S (Potential)	Fused Filament Fabrication System	Silicone Vascular Replicas	ABS 3D Printer	ABS

Table 1. Description of 3D Printing Method by Study (cont.)

Study Authors	Study	Application	Fabrication Method	Structure(s) Printed	Printer	Material(s)
Ishibashi et al. (2016)	Tailor-Made Shaping of Microcatheters Using Three-Dimensional Printed Vessel Models For Endovascular Coil Embolization	P/M	PolyJet	27 3D Vessel Models	Objet30 Pro™	Acrylic Resin (Vero™)
Thawani et al. (2016)	Three-Dimensional Printed Modeling of an Arteriovenous Malformation Including Blood Flow	P/M (Potential)	Stereolitho Graphic	Composite, Arterial, and Venous Models	ProJet 6000	Polycarbonate-Like Photoreactive Polymer
Baskaran et al. (2016)	Current Applications and Future Perspectives of the Use of 3D Printing in Anatomical Training and Neurosurgery	Literature Review	NA	NA	NA	NA
Pucci et al. (2017)	Three-Dimensional Printing: Technologies, Applications, and Limitations in Neurosurgery	Review of Technologies & Applications in Neurosurgery	NA	NA	NA	NA
Shakir et al. (2017)	Editorial: See One, Do One, Teach One? Paradigm Shift with Three-Dimensional Printing	Editorial	NA	NA	NA	NA
Wang et al. (2018)	3D Printing of Intracranial Aneurysm Based on Intracranial Digital Subtraction Angiography and Its Clinical Application	P/M, T/S	PolyJet	13 Aneurysms and Parent Vessels	Connex™ Multi-Material 3D Printer	Photosensitive Resin
Dong et al. (2018)	Three-Dimensional Brain Arteriovenous Malformation Models For Clinical Use and Resident Training	P/M, T/S	PolyJet; BinderJet	7 Basilar Arteriovenous Malformations	Stratasys J750™ or Spectrum Z TM 510 (3D Systems)	
Tenjin H, Okano Y (2017)	Training Model For Cerebral Aneurysm Clipping.	T/S	Polyvinyl Alcohol	14 Aneurysms		

Application: P/M = Surgical Planning & Modeling; T/S = Surgical Training & Simulation

Section Two:

Experience at the JI/GVI Using 3D Printed Models for **Neurovascular Pre-Surgical Planning and Training**

The Jacobs Institute (JI), a not-for-profit medical device innovation center, the Gates Vascular Institute (GVI), a vascular hospital, and the University at Buffalo's School of Medicine and School of Engineering are using patient-specific 3D printed vascular flow models in conjunction with patient imaging studies to plan for complex neuroendovascular procedures and to train university fellows, residents and industry engineers.

Pre-Surgical Planning

In terms of pre-surgical planning, the experience at the JI/GVI, like that described in many of the studies reviewed in part one (16,19), suggests that 3D printed models have the most to offer for challenging cases with complex anatomy that can confound even experienced surgeons. Patient-specific models allow JI-affiliated neurosurgeons to adjust endovascular treatment plans before the patient is actually in the room and to prepare for unanticipated challenges.

At the JI/GVI, most of the neurovascular models have been used to plan complex aneurysm interventions. As noted in much of the literature reviewed in part one (20,22,23), no two aneurysms are the same and require a full understanding of the vascular anatomy to ensure successful treatment. Unlike 3D images, the 3D printed models identify all of the involved vessels, which allows physicians to understand 3D spatial relationships.

Dr. Adnan Siddiqui, Chief Medical Officer at the JI, has used patient-specific 3D printed vascular models as part of his treatment planning process for three patients with challenging aneurysms. His first patient was a 47-year-old woman who presented with headaches and vision loss. Imaging revealed that the woman had a complex aneurysm

in her middle cerebral artery that Dr. Siddiqui thought could be treated with an intrasaccular device that resembles a metallic basket. He had a PolyJet model of the patient's vasculature printed in flexible TangoPlus™ to see if this device would work (Figure 2). During deployment of the device in the 3D printed model under fluoroscopy in a simulated cath lab, Dr. Siddiqui found that it was not ideal for this type of aneurysm and could cause potential complications (Figure 3).

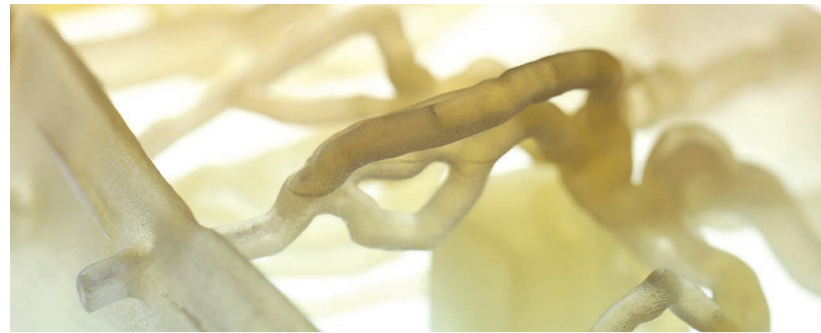

Figure 2. The 3D printed model, made with flexible TangoPlus photopolymer, gave the doctors the opportunity to not only inspect a life-sized replica of the aneurysm, but also conduct a series of pre-surgical tests against several treatment options.



Figure 3. The team at Jacobs Institute tests surgical approaches using a guidewire and 3D printed model which accurately reflects the anatomy of the patient.

Section Two

(cont.)

Therefore, he changed his strategy, saving time and avoiding wasted devices and potential complications. He went on to successfully treat the patient using traditional stent coiling.

Dr. Siddiqui's next two patients had fusiform vertebrobasilar aneurysms. This type of aneurysm can occur in any of the intracranial vessels, but it is mainly found in the posterior vertebrobasilar region where it has a particularly aggressive natural history. These aneurysms are considered to be among the most daunting lesions faced by neurosurgeons and no comprehensively effective treatment approach has been identified (25). While surgery is sometimes possible, these aneurysms are increasingly being treated with endovascular approaches involving flow-diverting stents and stent-assisted coiling.

The first of these two patients was a 66-year-old male with a large fusiform vertebrobasilar aneurysm (Figures 4 and 5). Because the diameter of the aneurysm was larger than the available flow diverters, Dr. Siddiqui printed a PolyJet model of the patient's vasculature to assess the feasibility of using another device as a flow diverter (Figure 6). Following his assessment using the 3D printed model, he was able to successfully deploy the stent in the patient.

“

I learned things that I will use for the rest of my career.”

Participant

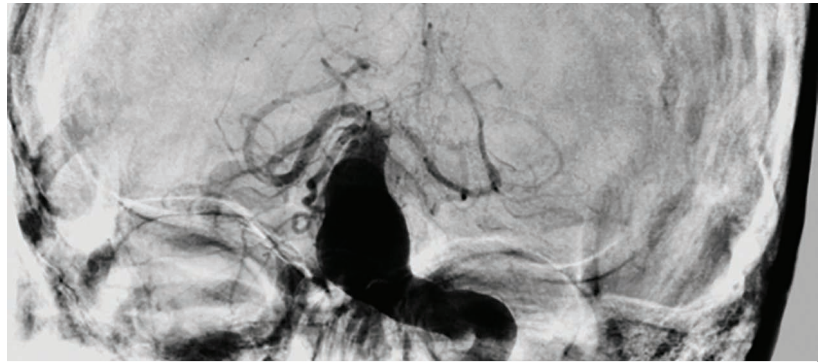


Figure 4. Patient with fusiform vertebrobasilar aneurysm (fluoroscopic image).

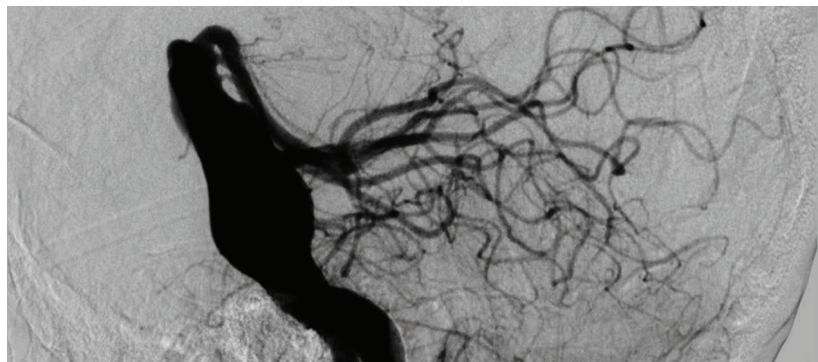


Figure 5. 3D spin of patient's aneurysm (angiographic reconstruction).




Figure 6. 3D printed model of vertebrobasilar aneurysm.

Section Two

(cont.)

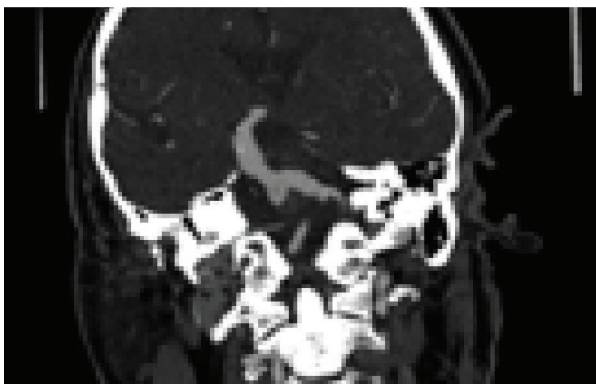


Figure 7. CTA of patient 2.

Dr. Siddiqui's second vertebrobasilar fusiform aneurysm patient was a 74-year-old male (Figures 7 and 8). Once he reviewed the patient-specific 3D printed PolyJet model (Figure 9), Dr. Siddiqui worked with a medical device company that customized one of its stents for use as a flow diverter. After a couple of deployment attempts in the PolyJet model, the flow diverter still did not work well. Further development work on the device was in progress when the patient passed away.

Surgeon Training

The Jacobs Institute and its partners also use patient-specific models to train neurosurgical residents and fellows to treat aneurysms and other neurovascular diseases. Prior to a 2016 course, the JI printed patient-specific models of a patient with multiple aneurysms, one with an anterior cerebral/middle cerebral (ACA/MCA) bifurcated aneurysm and one with an ophthalmic aneurysm. During the course, eleven neurosurgical residents from nine programs throughout the United States practiced deploying devices and treating stroke and aneurysms under fluoroscopy in the models in the JI's simulated cath lab. According to the JI affiliated physicians, the models allow physicians and physicians-in-training to learn and practice in the most life-like environments short of the catheterization lab. Using models in simulation environments in addition to lectures and

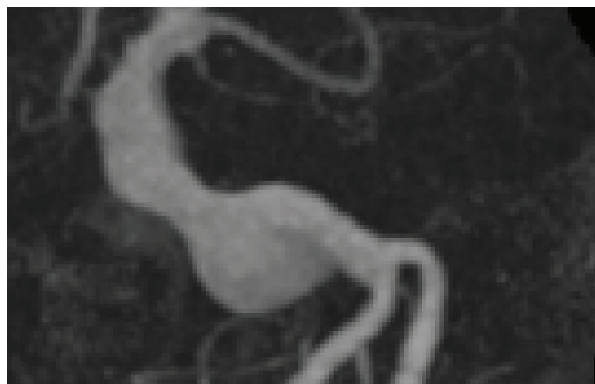



Figure 8. 3D spin of patient 2 (maximum intensity projection).

observation was, in the words of one participant, "part of a revolutionary program that will change the way endovascular neurosurgery is taught, learned and communicated."

The JI also uses patient-specific 3D printed models in its industry-facing clinical immersion program. In these programs, R&D engineers and sales representatives have the opportunity to deploy devices and prototypes in the models under fluoroscopy to gain insights into the behavior of their devices in ways that 3D images on a screen cannot provide. Apropos of the models, one participant noted that, "I learned things that I will use for the rest of my career."

Figure 9. 3D printed model of second vertebrobasilar aneurysm case.



Conclusion:

The Future of 3D Printed Models for Surgical Planning and Training

Based on the review of the literature and the experiences at the JI/GVI, the benefits of using patient-specific models for surgical planning for complex neuroendovascular cases can be categorized into benefits for the physician, the hospital, and most importantly, the patient. Their use in presurgical planning allows physicians to better visualize patient anatomy and practice in a safe, yet anatomically realistic environment so that they can more confidently create an appropriate surgical plan, choose appropriate devices, and be better prepared for potential complications. Using 3D printed models for surgical planning benefits the hospital in that it decreases operative time, ensures fewer devices are wasted, and ultimately leads to better outcomes. Finally, 3D printed models for surgical planning benefit the patient because they decrease operative time, sedation amount, and radiation exposure. Patients benefit from better physician skill and decision-making based on actual practice, which produces better outcomes.

Notwithstanding these benefits, the JI is actually using its engineered models to test medical devices in a simulated catheterization lab far more than for presurgical planning and even training purposes due to a number of barriers. These barriers include the absence of treatment planning reimbursements and the long time it

takes to move from scan to finished models due to software limitations, printing time, and post-processing requirements. In addition, using models for clinical decision-making requires that they demonstrate a high level of accuracy achieved through stringent controls in the model development and production process.

In order to expand adoption of 3D printed models as surgical planning tools, several things are needed. These include the following:

- The testing and validation of recipes for specific tissue materials and disease states
- The development of operational systems to track and verify patient ID from scan to model
- Development of model production systems akin to those used in industrial manufacturing that include quality systems, printer maintenance, and trained personnel
- The collection of compelling quantitative evidence of the positive impact of 3D printed vascular models on patient outcomes and on health care costs

The JI and its partners are committed to working across all of these needs so that patient-specific 3D printed models become a standard of care for all complex neurovascular cases.

References

1. Klein GT, Lu Y, Wang MY. 3D printing and neurosurgery-ready for prime time? *World Neurosurg.* 2013; 80: 233–235.
2. Waran V, Narayanan V, Karupiah R, et al. Neurosurgical endoscopic training via a realistic 3-dimensional model with pathology. *Simul Healthc.* 2015;10(1):43-8.
3. Randazzo M, Pisapia JM, Singh N, et al. 3D printing in neurosurgery: A systematic review. *Surg Neurol Int.* 2016; 7(33):S801-S809.
4. Anderson JR, Thompson WL, Alkattan AK, Diaz O, Klucznik R, Zhang YJ, et al. Three-dimensional printing of anatomically accurate, patient specific intracranial aneurysm models. *J Neurointerv Surg.* 2016;8:517–20.
5. Mashiko T, Otani K, Kawano R, Konno T, Kaneko N, Ito Y, et al. Development of three-dimensional hollow elastic model for cerebral aneurysm clipping simulation enabling rapid and low cost prototyping. *World Neurosurg.* 2015;83:351–61.
6. Khan IS, Kelly PD, Singer RJ. Prototyping of cerebral vasculature physical models. *Surg Neurol Int.* 2014;5:11.
7. Tai BL, Rooney D, Stephenson F, Liao P, Sagher O, Shih AJ, et al. Development of a 3D-printed external ventricular drain placement simulator: Technical note. *J Neurosurg.* 2015;123:1–7.
8. Weinstock P, Prabhu SP, Flynn K, Orbach DB, Smith E. Optimizing cerebrovascular surgical and endovascular procedures in children via personalized 3D printing. *Neurosurgery.* 2015;16:1–6.
9. Mashiko T, Konno T, Kaneko N, Watanabe E. Training in brain retraction using a self-made three-dimensional model. *World Neurosurg.* 2015;84:585–90.
10. Wurm G, Lehner M, Tomancok B, Kleiser R, Nussbaumer K. Cerebrovascular biomodeling for aneurysm surgery: Simulation-based training by means of rapid prototyping technologies. *Surg Innov.* 2011;18:294–306.
11. Ionita CN, Mokin M, Varble N, Bednarek DR, Xiang J, Snyder KV, et al. Challenges and limitations of patient-specific vascular phantom fabrication using 3D PolyJet printing. *Proc SPIE Int Soc Opt Eng.* 2014;9038:90380M.
12. Kondo K, Nemoto M, Masuda H, Okonogi S, Nomoto J, Harada N, et al. Anatomical reproducibility of a head model molded by a three-dimensional printer. *Neurol Med Chir.* 2015;55:592–8.
13. Namba K, Higaki A, Kaneko N, Mashiko T, Nemoto S, Watanabe E. Microcatheter shaping for intracranial aneurysm coiling using the 3-dimensional printing rapid prototyping technology: preliminary result in the first 10 consecutive cases. *World Neurosurg.* 2015;84:178–86.
14. Wurm G, Tomancok B, Pogady P, Holl K, Trenkler J. Cerebrovascular stereolithographic biomodelling for aneurysm surgery. Technical note. *J Neurosurg.* 2004;100:139–45.
15. Xu WH, Liu J, Li ML, Sun ZY, Chen J, Wu JH. 3D printing of intracranial artery stenosis based on the source images of magnetic resonance angiograph. *Ann Transl Med.* 2014;2:74.
16. Shakir HJ, Shallwani H, Levy EI. Editorial: See One, Do One, Teach One? Paradigm shift with three-dimensional printing. *Neurosurgery.* 2017; 80(1):3-5.
17. Pucci, J. et al. Three-dimensional printing: technologies, applications, and limitations in neurosurgery. *Biotechnology Advances.* 2017; 35:521-529.
18. Baskaran V, Štrkalj G, Štrkalj M, Di Ieva A. Current applications and future perspectives of the use of 3D printing in anatomical training and neurosurgery. *Front Neuroanat.* 2016;10:69.
19. Russ M, O'Hara R, Settur Nagesh SV, Mokin M, Jimenez C, Siddiqui A, Bednarek D, Rudin S, Ionita C. Treatment planning for image-guided neuro-vascular interventions using patient-specific 3D printed phantoms. *Proc SPIE Int Soc Opt Eng.* 2015; 9417.
20. Thawani JP, Pisapia JM, Singh N, Petrov D, Schuster JM, Hurst RW, Zager EL, Pukenas BA. Three-dimensional printed modeling of an arteriovenous malformation including blood flow. *World Neurosurg.* 2016; 90:675-683.
21. Frölich AM, Spallek J, Brehmer L, Buhk JH, Krause D, Fiehler J, Kemmling A. 3D printing of intracranial aneurysms using fused deposition modeling offers highly accurate replications. *AJNR Am J Neuroradiol.* 2016 Jan;37(1):120-4.
22. Wang JL, Yuan ZG, Qian GL, Bao WQ, Jin GL. 3D printing of intracranial aneurysm based on intracranial digital subtraction angiography and its clinical application. *Medicine.* 2018; 97(24):e111103.
23. Dong M, Chen G, Li J, Qin K, Ding X, Peng C, Zhou D, Lin X. Three-dimensional brain arteriovenous malformation models for clinical use and resident training. *Medicine.* 2018; 97(3):e9516.
24. Kaneko N, Mashiko T, Ohnishi T, Ohta M, Namba K, Watanabe E, Kawai K. Manufacture of patient-specific vascular replicas for endovascular simulation using fast, low-cost method. *Sci Rep.* 2016; 6:39168.
25. Siddiqui AH, Abila AA, Kan P, Dumont TM, Jahshan S, Britz GW, Hopkins LN, Levy EI. Panacea or problem: flow diverters in the treatment of symptomatic large or giant fusiform vertebrobasilar aneurysms. *J Neurosurg.* 2012; 116(6):1258-66.
26. Aoun RJ, Hamade YJ, Zammar SG, Patel NP, Bendok BR. Futuristic Three-dimensional printing and personalized neurosurgery. *World Neurosurg.* 2015; 84(4):870-1.
27. Tenjin H, Okano Y. Training model for cerebral aneurysm clipping. *Interdisciplinary Neurosurgery.* 2017; 10: 114-118.

Stratasys Headquarters

7665 Commerce Way,
Eden Prairie, MN 55344
+1 800 801 6491 (US Toll Free)
+1 952 937-3000 (Intl)
+1 952 937-0070 (Fax)

stratasys.com

ISO 9001:2015 Certified

1 Holtzman St., Science Park,
PO Box 2496
Rehovot 76124, Israel
+972 74 745 4000
+972 74 745 5000 (Fax)

© 2019 Stratasys Ltd. All rights reserved. Stratasys, Stratasys signet, PolyJet, Objet, Objet30 Pro, Vero, Connex, Objet Eden260V and J750 are trademarks or registered trademarks of Stratasys Ltd. and/or its subsidiaries or affiliates and may be registered in certain jurisdictions. All other trademarks belong to their respective owners. Product specifications subject to change without notice. Printed in the USA. WP_PJ_ME_Neurosurgery Jacobs Institute WhitePaper_0919a

